


1. Case number : 01
2. Case title : Delayed neurological manifestations following Viper bite
in Srilanka ; A case report
3. Author's name : D M J M H Ambagammana
4. Name of the patient : Mr Pradeep Kumara
5. Date of admission : 01/05/2020
6. Date of discharge : 06/05/2020
7. BHT number : 45829/2020
8. Age : 17 years
9. Year : 2020
10. Signature of the supervisor : 

PROF. SISIRA SIRIBADDANA
MBBS MD FCCP FRCP
Senior Professor & Chair
Department of Medicine
Faculty of Medicine & Allied Sciences
Rajarata University of Sri Lanka
SLMC Reg. No. 9134

Delayed neurological manifestations following Viper bite in Sri Lanka ; A case report

Ambagamma D M J M H(MBBS), Sisira Siribaddana(MBBS,MD,FCCP,FRCP)Senior professor of Medicine

Teaching Hospital ,Anuradhapura.

Key words: Russell's viper, envenomation, neurotoxicity, coagulopathy.

Abstract

Venomous snake bites are common in Sri Lanka and it leads to high case related mortality and morbidity. Neurotoxicity, coagulopathy and local reactions of envenomation are the main initial manifestations. This is a case of a young male presented with a snake bite who had coagulopathy and neurological manifestation which improved after anti venom serum(AVS). After 23 hours of the bite this patient had worsening of neurological manifestations which was settled spontaneously between next 24 hours without any specific treatment.

Introduction

Snake bites are a common public health issue in Sri Lanka as it is a tropical country[1]. Elapidae, viripidae and colubridae are the main families of venomous snakes in south east asia[1]. Russell's viper bite is a common cause of hospital admission after a snake bite and It is more prevalent among males and specially in young age[2]. There are two peaks of Russels viper bites within the country in an year corresponding to paddy & chena cultivation, one peak is March and April, and the other one in October and November[2]. This patient also presented in month of April in 2020. This case created a dilemma regarding the possible course of further action as new delayed neurological manifestations developed later which created significant neurological weakness.

Patient information

A 17 year old male presented to a local hospital after 30 minutes of Russell's viper bite while on the way home. He had severe pain at the bite site. He was transferred to Teaching Hospital Anuradhapura for further evaluation and management. On admission to the Teaching Hospital he had abdominal pain with 2 episodes of vomiting but he did not have any bleeding manifestations.

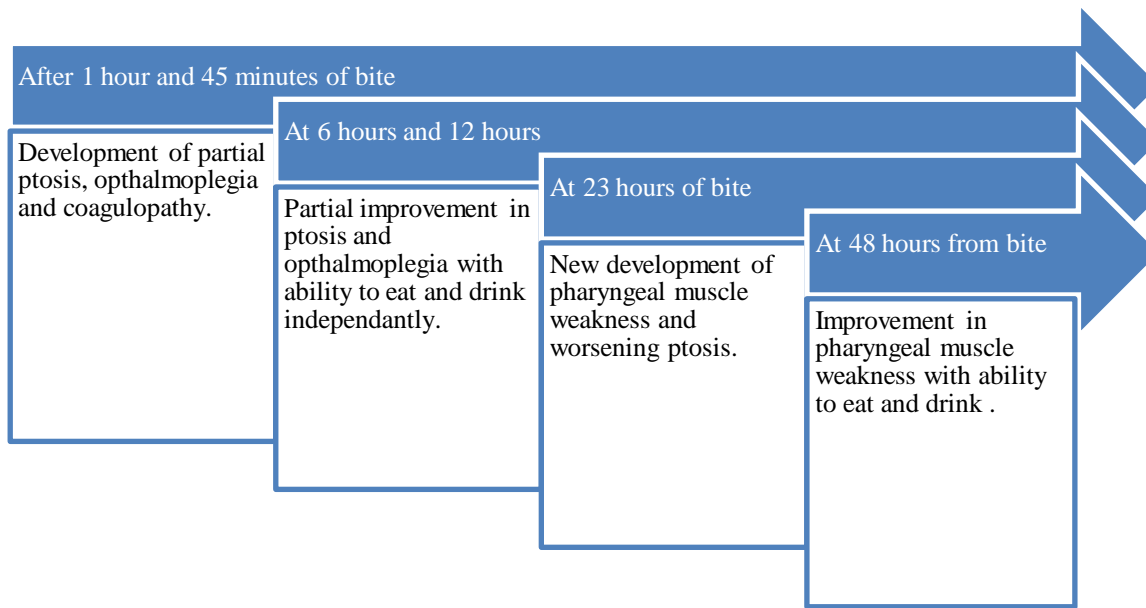
Clinical findings

He had developed partial ptosis and mild ophthalmoplegia, one hour and 45 minutes after the bite . His consciousness was normal with proper orientation in time, person and place. His pulse rate was 120 bpm, blood pressure was 90/60 mmHg. His respiratory rate was 22 cycles/min. Tidal volume 600ml from Wright's respirometer. He had the bite at right side foot with fang marks and local swelling. His abdominal examination was normal. 6 hours after the initial anti venom dose administration he improved clinically with ability to eat and drink normally . He had right side foot swelling , partial ptosis and mild ophthalmoplegia.

After 12 hours of the bite he was clinically stable without bleeding manifestations. His urine colour was normal with normal urine output.

23 hours after the bite, he developed worsening of ptosis, ophthalmoplegia , pharyngeal muscle weakness(figure 01,02) But his limb muscle power was normal. Tidal volume was 550 ml and single breath count was 21. His urine color was dark.

Timeline



Diagnostic assessment and therapeutic intervention

The on admission Whole blood clotting time was more than 20 minutes. His clinical findings were compatible with envenomation of Russell’s viper. He was immediately treated with 20 vials of anti venom serum(AVS) in 200 ml of normal saline over 1 hour. He was premedicated with sub cutaneous adrenaline 0.25mg. He was kept under close monitoring but no anaphylaxis was noted.His tidal volume was monitored 3 hourly and was normal. His initial investigations were as follows, WBC= 9630 / μ L,Hb=13.9 g/dl, platelets= 73000/ μ L, INR=2.27, Serum creatinine= 83 μ mol/l, Na⁺= 136mmol/l, K⁺= 3.0 mmol/l.

After 12 hours of bite, His whole blood clotting time was normal with INR of 1.7 , WBC =18400/ μ L, Hb= 13.2 g/dl and platelets= 200000/ μ L.

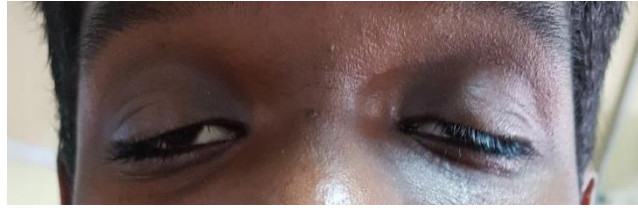
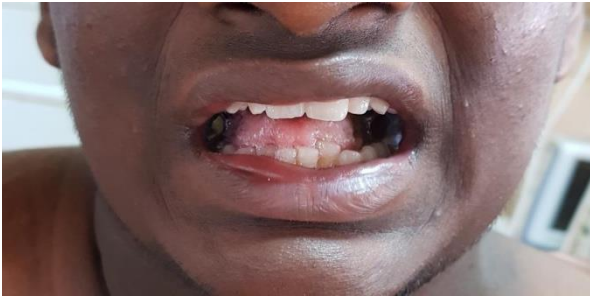
Figure 01. Pharyngeal and facial muscle weakness Figure 02. Worsening of ptosis.

After development of late onset neurological manifestations at 23 hours from the bite he was not treated with AVS. He was kept nil by mouth and continued monitoring of blood pressure, pulse rate and tidal volume for next 16 hours. He was hydrated with intravenous 0.9% sodium chloride 100 ml/ hour . His serum creatinine was $97\mu\text{mol/l}$, $\text{Na}=138\text{mmol/l}$, $\text{K}=3.9\text{mmol/l}$, corrected Ca 2.45 mmol/l ,WBCT =normal ,INR= 1.5,Creatinine kinase= 3900 IU/l , Blood picture showed low grade microangiopathic haemolysis.

Follow up and outcomes

He was kept under close monitoring and we observed partial improvement of ophthalmoplegia and ptosis with complete improvement of pharyngeal muscle weakness.His urine output was more than 1ml/kg/hour with normal vital parameters.His right foot swelling was gradually improved. He was well hydrated with oral fluids while monitoring the parameters for another 2 days. On the 4th day of hospitalization, he was discharged and reviewed after 1 week. His investigations were normal with complete clinical recovery.

Discussion

Snake bites are common in south East Asia[1].It is a common acute medical problem in Sri Lanka.These bites can be classified as venomous and nonvenomous. Srilankan highly venomous snakes are Russell's viper, Cobra, Common krait, Ceylon krait, Merrem's and Lowland hump-nosed pit-viper. Among them Russell's viper (*Daboia russelii*) is common in all types of habitats and is particularly abundant in dry zone forests and paddy cultivations. Snake venom contains multiple toxins. It can be either enzymes, non enzymatic toxins or both [5].Russell's viper envenoming commonly causes local swelling , neurotoxicity, coagulopathy and acute kidney injury (AKI). Coagulopathy manifestations are spontaneous bleeding such as haematuria, Gastro intestinal bleeding, mucosal bleeding, prolonged clotting time, in-coagulable blood. These features are due to presence of Metalloproteinases, serine proteases, and C-type lentins in the snake venom [4].Neurological manifestations are ptosis, external ophthalmoplegia and blurred vision and respiratory failure occurs due to neurotoxins like phospholipase A_2 and three-finger protein [4,5]. Ptosis, ophthalmoplegia and bulbar muscle weakness are the common features and respiratory muscle weakness was rare [6].Other rare manifestations are hemiparesis, coma, lowering in Glasgow Coma Scale (GCS),convulsions, expressive dysphasia and blindness[2,8].

This patient initially developed ptosis and ophthalmoplegia as neurological manifestations with local swelling. As this patient developed systemic envenoming features and coagulopathy we have given anti venom serum . With anti venom serum his neurological manifestations were improved. In general neurological manifestations develop within 8 hours of bite [9] but in this case new neurological features developed after 22-23 hours of the initial bite. The common neurological manifestations are ptosis, ophthalmoplegia and pharyngeal muscle weakness but pharyngeal muscle weakness is less common than other neurological features.[8]. In this case also new onset pharyngeal muscle weakness developed at 22 hours with worsening ptosis, pharyngeal muscle weakness and ophthalmoplegia. We have done thorough neurological examinations to differentiate from brain stem stroke as ischemic strokes are recognized after Russell's viper bite[6]. We did not repeat anti venom serum because there were no indication to repeat anti venom according to the current Sri Lanka Medical Association guideline on management of snake bites . Although we did not repeat anti venom serum , patient improved spontaneously after 24 hours. During this period patient could not take oral meals including liquids therefore intravenous fluids were given to maintain his adequate intake. As they are more prone to get acute renal failure adequate hydration with crystalloids was the best method to reach daily fluid intake. These neurological manifestations are fully cleared and patient is normal in day 3-5 days [7,8]. This case emphasizes the importance of close observation of patients with Russell's viper bite for early and delayed neurological manifestations.

Conclusion

Russell's viper bite can cause neurological new manifestations even after 24 hours of bite. Careful observation and watchful waiting is the best method to treat these patients without repeating the anti venom serum.

Patient perspective

He revealed that he had afraid about worsening of symptoms even after the treatment.

Informed consent

Consent was given by the patient to publish this clinical scenario that happened to him.

References

1. World Health Organization, 2016, Guidelines for the management of snake-bites.
2. Kularatne SA. Epidemiology and clinical picture of the Russell's viper (*Daboia russelii russelii*) bite in Anuradhapura, Sri Lanka: a prospective study of 336 patients. *Southeast Asian J. Trop. Med. Public Health*. 2003 Dec 1;34(4):855-62.
3. Manappallil RG. Delayed neurological manifestation in viper bite despite anti-snake venom therapy. *Int J Adv Med*. 2017 Jan;4(1):286.
4. Del Brutto OH, Del Brutto VJ. Neurological complications of venomous snake bites: a review. *Acta Neurol Scand*. 2012 Jun;125(6):363-72.

5. Ranawaka UK, Lalloo DG, de Silva HJ. Neurotoxicity in snakebite--the limits of our knowledge. *PLoS Negl Trop Dis*. 2013 Oct 10;7(10):e2302.
6. Gawarammana I, Mendis S, Jeganathan K. Acute ischemic strokes due to bites by *Daboia russelii* in Sri Lanka--first authenticated case series. *Toxicon*. 2009 Sep 15;54(4):421-8.
7. Silva A, Maduwage K, Sedgwick M, Pilapitiya S, Weerawansa P, Dahanayaka NJ, Buckley NA, Siribaddana S, Isbister GK. Neurotoxicity in Russell's viper (*Daboia russelii*) envenoming in Sri Lanka: A clinical and neurophysiological study. *Clin Toxicol (Phila)*. 2016 May 27;54(5):411-9.
8. Seneviratne U, Dissanayake S. Neurological manifestations of snake bite in Sri Lanka. *J Postgrad Med*. 2002 Oct 1;48(4):275.